



## A Study of Arterial Vasculature of Thumb in Human Cadavers

Pramila Padmini M\*

*Department of Anatomy, Gitam Institute of Medical Sciences and Research, Rushikonda, Visakhapatnam, Andhra Pradesh, India*

\*Corresponding e-mail: [pmishra@gitam.edu](mailto:pmishra@gitam.edu)

### ABSTRACT

*An adult male cadaver in which the left superficial palmar arterial arch is completed by a superficial palmar branch from the radial artery and giving rise to 1 proper and 4 common palmar branches. The first common palmar branch was a common trunk for the arteria princeps pollicis and arteria radialis indicis. The radial artery which passed on to the dorsal side did not give any branches to the thumb. The entire arterial supply to the left thumb was provided by the superficial palmar arch, which was the common trunk. The thumb is the distinguishing character of the human hand. The importance to the arterial supply of the thumb in the present case was that it is solely provided by the superficial palmar arch. A potential lethality could exist in the event of traumatic injury to the superficial palmar arch.*

**Keywords:** Arteria princeps pollicis, Radial artery, Arteria radialis indicis, Superficial palmar arch

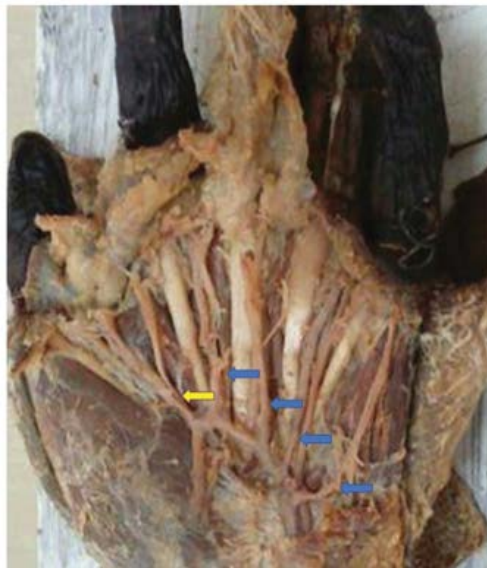### INTRODUCTION

The thumb is the distinguishing character of the human hand. Humans have significantly larger first ray in comparison to other primates which permits better opposition and allows better utilization of the other fingers in different types of grips and pinch finger strength. The thumb contributes to 40% of hand function and is critical for gripping actions and fine prehension [1]. Hence, appropriate management of thumb trauma, as well as reconstruction of thumb, is of prime importance for functional rehabilitation. According to Hollinshead, the Arteria Princeps Pollicis (APP) may alternatively arise directly from the deep palmar arch, or it may also arise from a common trunk with the radialis indicis; and while both are typically derived from the radial artery, they commonly have collateral circulation available to them from the ulnar artery by way of the superficial palmar arch or one of its branches [2].

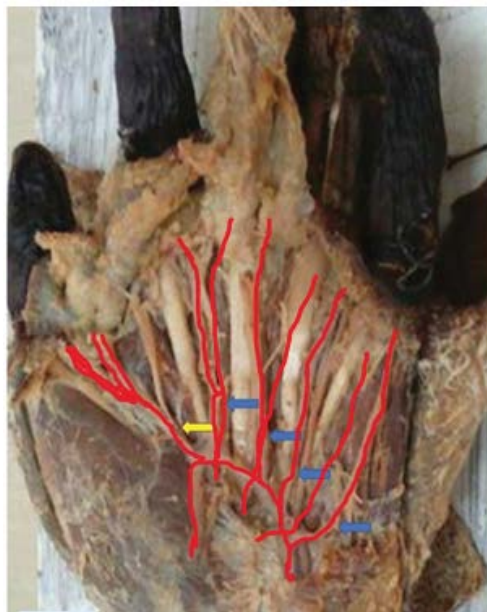
### MATERIALS AND METHODS

70 cadavers were examined during the period 2004-2015, 2017, 2019 as a part of the routine dissection. The superficial palmar arch was exposed, and all the branches were traced out. 10 cadavers have shown incomplete superficial palmar arch unilaterally and normal formation of the arch with the superficial palmar branch of the radial artery. One such incomplete superficial palmar arch presented was published by some of my colleagues and myself [3].

During the study, in an adult male cadaver, the left superficial palmar arterial arch had given rise to 5 branches (1 proper and 4 common) and the first common palmar branch was giving rise to a common trunk for the arteria princeps pollicis and radialis indicis (Figure 1) and a line diagram of the same is represented in Figure 2. The common trunk arose from the superficial palmar arch at the point of origin of the first lumbrical from the tendon of the flexor digitorum profundus. The APP then continued along the medial border of the thumb providing its sole nutrient supply by way of a terminal trifurcation into the dorsal ulnar, palmar ulnar, and palmar radial arteries of the thumb. The dorsal radial artery of the thumb did not give any branches to the thumb and has taken part in the formation of the deep palmar arch. Accordingly, the entire arterial supply to the left thumb was provided by the superficial palmar arterial arch. This was a unilateral variation found only in 1 cadaver. On the right side, it was a normal pattern where 1 proper and 3 common palmar branches are given off by superficial palmar arch and the thumb was supplied by radialis indicis and arteria princeps pollicis given off by radial artery.



**Figure 1** Yellow arrow showing arteria princeps pollicis and radialis indicis arising from the superficial palmar arch; blue arrow shows 1 proper and 3 common palmar branches



**Figure 2** Line Diagram; Yellow arrow showing arteria princeps pollicis and radialis indicis arising from the superficial palmar arch; blue arrow shows 1 proper and 3 common palmar branches

## DISCUSSION

The arterial supply of the thumb can arise from a combination of the APP, the first common palmar digital artery of the superficial palmar arch, and the first dorsal metacarpal artery [4]. The pattern of anastomoses of these three arteries is very complex when they pass near the metacarpophalangeal joint. The Princeps Pollicis Artery (PPA) is generally considered the largest source for the palmar arteries of the thumb [5,6]. Murakami, et al 1969 proposed a classification based on the origin and proximal course of the PPA [6]. Their classification involved three major types and four intermediate, rather anomalous types.

Loukas, et al. reported that the superficial palmar arch was derived solely from the ulnar artery with no contribution

from radial elements in 35% of the cases [7]. Our study also showed 12% of cases where the superficial palmar arch is formed solely by the ulnar artery and is quite common.

Clinically, the arterial blood supply of the thumb is important. Parks, et al. 1998 highlighted four case reports where occlusion of the radial artery or surgical manipulation of the Princeps Pollicis Artery (PPA) led to pain, paresthesia, or gangrene of the thumb and index finger [8].

In a study done by AY Nasr 2012, they found, the radialis indicis branch originated from the radial artery in 51 out of 60 (85%) upper limbs, and it was absent in 4 limbs, while the superficial palmar arch gave the origin of this branch in 5 male upper limbs (6.7%) [9]. In female upper limbs, the radialis indicis branch was absent in 3 out of 40 (7.5%) upper limbs while it originated from the radial artery in 34 out of 40 upper limbs, and in 3 upper limbs (7.5%) it arose from the superficial palmar arch. The radial artery was the origin of the radialis indicis branch in 85 out 100 (85%) upper limbs while the superficial palmar arch gave the origin of the radialis indicis branch in 8 out 100 upper limbs. In 91 (91%) upper limbs, this branch originated from the radial artery while in 8 out 100 upper limbs, it was a branch of the superficial palmar arch of the hand.

In the present study out of a total of 70 cadavers, only one cadaver showed arteria princeps pollicis and radialis indicis given off by superficial palmar arch. This study was presented as many studies are not available in the literature regarding the variation in the arterial supply of thumb. Hence, a hand surgeon should be well versed in the vascular anatomy of the thumb which varies from that of the fingers. Determination of dominant vascular channels in different anatomical regions is important for prioritizing surgical approaches. This variation must be kept in mind during any vascular, reconstructive, cardiac, orthopedic, or radiological manipulations. It remains important to continually report significant anatomical vascular variations so that clinicians are aware of these anomalies and thus avoid the potential consequences associated with them.

## DECLARATIONS

### Conflicts of Interest

The authors declared no potential conflicts of interest concerning the research, authorship, and/or publication of this article.

### Acknowledgment

I thank Dr. B. Narasinga Rao sir, former Professor of Anatomy for his encouragement. The author acknowledges the immense help received from the scholars whose articles are cited and included in references of this manuscript. The authors are also grateful to authors/editors/publishers of all those articles, journals, and books from where the literature for this article has been reviewed and discussed.

## REFERENCES

- [1] Kleinman, W. B., and J. W. Strickland. "Thumb reconstruction." *Green's Operative Hand Surgery*, Vol. 2, 1999, pp. 2068-170.
- [2] Hollinshead, W. H. "Anatomy for Surgeons, Vol. 3 The Back and Limbs 2. eds." 1969.
- [3] Rani, Ch Roja, B. Narasinga Rao, and M. Pramila Padmini. "Unilateral incomplete superficial palmar arch-A case report." *International Journal of Current Research and Review*, Vol. 4, No. 20, 2012, pp. 125-26.
- [4] Ikeda, Akira, et al. "Arterial patterns in the hand based on a three-dimensional analysis of 220 cadaver hands." *The Journal of Hand Surgery*, Vol. 13, No. 4, 1988, pp. 501-09.
- [5] Anson, Barry J. "Atlas of human anatomy, Philadelphia." *B. Saunders Company*, 1950.
- [6] Murakami, Takuro, Kenichi Takaya, and Hiromu Outi. "The origin, course and distribution of arteries to the thumb, with special reference to the so-called A. princeps pollicis." *Okajimas Folia Anatomica Japonica*, Vol. 46, No. 2-3, 1969, pp. 123-37.
- [7] Loukas, Marios, Danny Holdman, and Shelly Holdman. "Anatomical variations of the superficial and deep palmar arches." *Folia Morphologica*, Vol. 64, No. 2, 2005, pp. 78-83.

- [8] Parks, Barbara J., Juan Arbelaez, and Robert L. Horner. "Medical and surgical importance of the arterial blood supply of the thumb." *The Journal of Hand Surgery*, Vol. 3, No. 4, 1978, pp. 383-85.
- [9] Nasr, A. Y. "The radial artery and its variations: anatomical study and clinical implications." *Folia Morphologica*, Vol. 71, No. 4, 2012, pp. 252-62.