



## COVID-19 Infection in Asymptomatic Full Term Pregnancy-Presentation of a Case with Management Approach

Priyanka Singh<sup>1\*</sup>, Neema Acharya<sup>1</sup>, Sourya Acharya<sup>2</sup>, and Shazia Mohammad<sup>1</sup>

<sup>1</sup>Department of Obstetrics and Gynecology, Jawaharlal Nehru Medical College, Datta Meghe Institute of Medical Sciences, Sawangi, Wardha, India

<sup>2</sup>Department of Medicine, Jawaharlal Nehru Medical College, Datta Meghe Institute of Medical Sciences, Sawangi, Wardha, India

Corresponding e-mail: [Priyanka.singh044@gmail.com](mailto:Priyanka.singh044@gmail.com)

### ABSTRACT

Pregnancy and childbirth not only increase the risk for acquiring SARS-CoV-2 infection, but may worsen the clinical course of COVID-19. The number of new COVID-19 cases and deaths globally slightly decreased this week, with over 5.5 million cases and over 90,000 deaths. Case and death incidences, however, remain at the highest levels since the beginning of the pandemic. The choice to use a specific drug for COVID-19 in pregnancy should take into account. The drugs usually have benefits and possible adverse events in each single case. In this overview it will provide useful information for obstetricians for appropriate management for antenatal care in COVID-19. There are many challenges which mandate an integrated approach to pregnant woman's who are affected by SARS-CoV-2. Here we present a case of asymptomatic COVID-19 in pregnant woman with non-classic diagnostic imaging modalities such as computed tomography findings and focused on medical management in this situation in order to prevent maternal and fetal complications in future. The medical management provided to COVID-19 positive during pregnancy and post-operative responded well to antibiotics such as azithromycin with mild computed tomography severity score recovered well soon.

**Keywords:** Coronavirus, COVID-19, SARS-CoV-2, Pregnancy, diagnostic, Management, Childbirth, Risk

### INTRODUCTION

About two-thirds of pregnant women with COVID-19 have no symptoms at all (also known as being asymptomatic). Most pregnant women who do have symptoms only have mild cold or flu-like symptoms. However, a small number of pregnant women can become unwell with COVID-19. Pregnant women who catch COVID-19 may be at increased risk of becoming severely unwell particularly in the third trimester [1-3].

The coronavirus epidemic increases the risk of perinatal anxiety and depression, as well as domestic violence. It is critically important that support for women and families is strengthened as far as possible; that women are asked about mental health at every contact [4].

Pregnancy with COVID-19 must be considered as an increased risk case and intensive monitoring must be done including foetal heart rate and contractions monitoring.

Antenatal examination and ultrasound may require detailed planning. Minimal equipment must be used, single probe ultrasonic examination must be done and the instruments and the room adequately disinfected after examining a Suspect or a known case [5].

The main purpose of the study is to discuss the management approach to COVID-19 infection through diagnostic modalities, investigations and proper assessment for better maternal and perinatal outcome for COVID-19 patients in

pregnancy.

### CASE REPORT

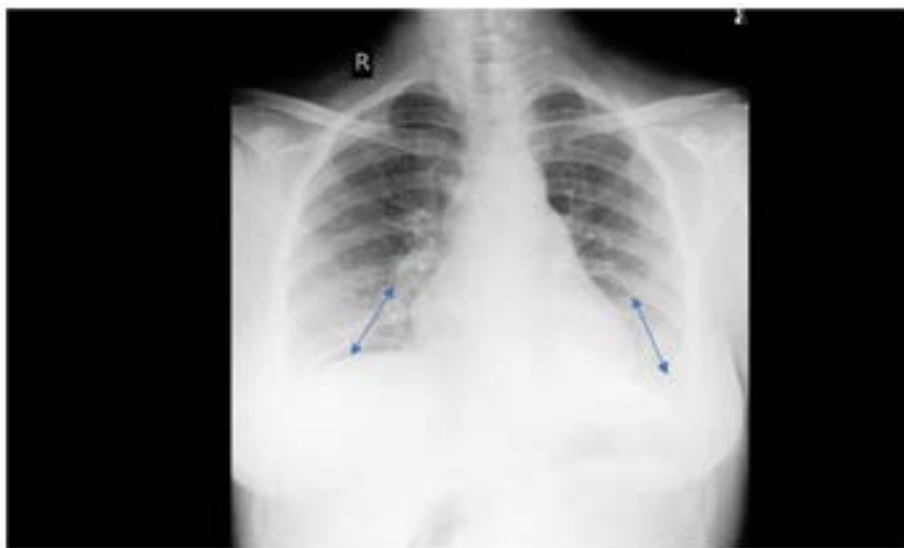
A 22 year old unbooked with gravida 2 and abortion 1 with 39 weeks of gestation presented in emergency hours with pain in abdomen on and off since 1 day. She had no history of fever, cough and cold with a short visit to her maternal place for 7 day to Amravati one month back. She had history of spontaneous abortion one and half year back. Fetal ultrasound scan findings were under normal limits.

With this background, patient was examined by Senior Resident in casualty after taking all the preventive measures with Personal Protective Equipment [6].

On Examination she was afebrile, pulse rate- 90 beats per minute, blood pressure-126/80 mmHg, SPO2-98% with pallor and edema absent. Air entry was equal on both sides. There was no adventitious sound. On per abdomen examination fundal height was term size, there was single foetus in cephalic presentation with floating head in left occipito anterior position. There was foetal tachycardia with foetal heart rate of 150 bpm. Vaginal examination revealed unripe cervix with vertex in left occipito anterior position which was above pelvic rim.

COVID Antigen test for SARS-CoV-2 was done in casualty which turned out to be positive.

On pulmonologist opinion, shielded chest X-ray was done which revealed peripheral patch opacities are seen in lower zone of both the lung fields suggestive of consolidation seen in Figure 1.



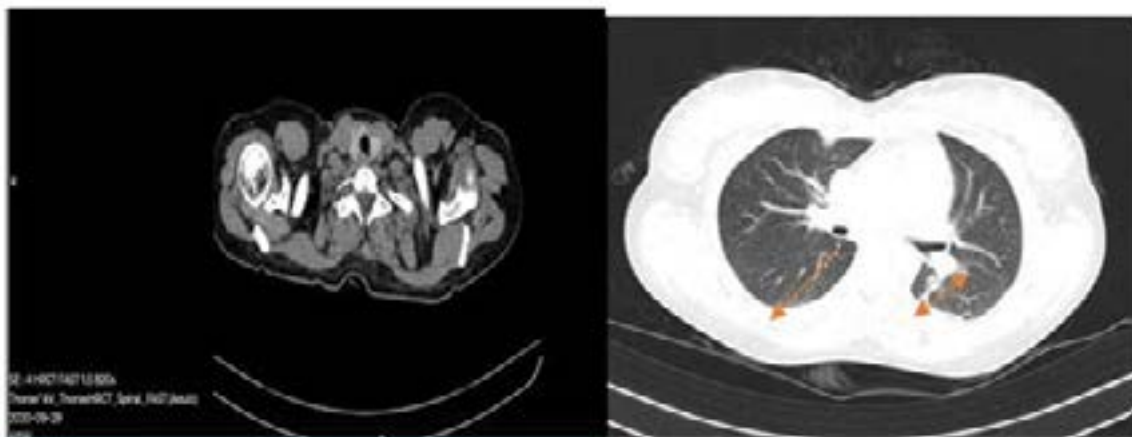
**Figure 1 Chest radiograph of patient showing peripheral patch opacities in lower zone in both lung fields suggestive of consolidation**

Patient was shifted to COVID positive isolation ward. A routine investigation was sent. The complete blood counts revealed haemoglobin of 11.4 gm/dl, total leucocyte count-6700/cumm, total platelet count-2.83 lacs/cu mm, C-Reactive protein level-9 mg/L and D-dimer level-0.56 respectively.

After 8 hours patient was shifted for emergency caesarean section in view non reassuring Non Stress test with fetal distress. Caesarean section was conducted by wearing Personal Protective Equipment (PPE) and other preventive measures by senior residents and consultants. A female baby was delivered by vertex presentation at 8:43 pm of weight 4 kg with APGAR score 8/10, 9/10. Baby was immediately shifted to NICU for COVID-19 evaluation. Patient was managed in isolation ward and postoperative period was uneventful.

After 2 days post-operative lower segment Caesarean Section, on Pulmonologist opinion High Resolution Computed Tomography Thorax (HRCT-thorax) was carried out for further evaluation. The reporting revealed sub segmental

atelectasis right side and consolidation on left side with moderate bilateral pleural effusion in view of COVID positive PCR test imaging CT severity score-4/25.



**Figure 2 HRCT Thorax reveals sub segmental atelectasis right side and consolidation on left side with moderate bilateral pleural effusion in view of COVID positive PCR test imaging grading is CORAD 6 and CT severity score-4/25**

A physician call was noted in view of consolidation of left lung. On physician opinion Tablet Azithromycin 500 mg OD, Tablet Limcee 500 mg BD, Ivermectin 12 mg OD was started for 5 days. Counselling for pros and cons of breastfeeding was done and patient was opted for exclusive breast feeding. Patient responded well to medical management was discharged home with a healthy baby on 10th post-operative day. She was advised quarantine at her place for another two weeks.

### DISCUSSION

In our study, a full term asymptomatic pregnant woman visited us and after doing her RT-PCR for COVID-19 swab test she came out to be positive. Post operatively her HRCT thorax revealed non classic computed tomographic imaging showing consolidation in left lung with CT severity score 4/25 which responded well to antibiotics medication and recovered completely without any hassle. Azithromycin is well studied in pregnancy and its use for COVID-19 pregnant patients and it does not seem to cause any fetal risks from its use in other conditions.

The imaging and clinical features of the patients with COVID-19 in late pregnancy, Clinical condition with Chest CT finding responded well to clinical condition but hepatic toxicity of antiviral drugs may cause the delayed recovery of liver function in the patient [7].

The study proved clinical recovery from severe COVID-19 was high in women who initiated remdesivir during pregnancy (93%) or the immediate postpartum period (median postpartum day 1 (89%) [8].

The patient received hydroxychloroquine and remdesivir. Hydroxychloroquine proved have some efficacy in COVID-19, although still in hypothetical situation. More recent data have demonstrated a mortality benefit from dexamethasone in severe COVID-19 as it crosses the placenta during pregnancy which could help to clinically improve maternal condition [9].

Tocilizumab for use in pregnant women with COVID-19 are scarce, it has been used in pregnant women with rheumatic disease with no increase in birth defects or miscarriage. After a single dose of tocilizumab, C-reactive protein concentrations began to improve and normalized within 6 days which could help to provide better maternal and fetal outcome [10].

### CONCLUSION

It's always a challenging situation for management of COVID-19 in pregnancy. Antivirals are proved to be more

compatible in pregnant and lactating patients with COVID-19. Our study demonstrates that most of the pregnant cases were asymptomatic and atypical on clinical findings which faced difficulty in early detection. Early detection of symptomatic patient will be more helpful during screening with haematological investigation and swab testing in these pregnant women. Thus these diagnostic modalities and medical treatment will promptly help early detection and reduce maternal and perinatal outcomes. Use of preventive measure and counselling would not only help healthcare worker to provide with utmost moral support but would also help to tackle anxiety of pregnant woman's to deal with COVID-19 during later stages in their pregnancies.

#### DECLARATIONS

##### Conflicts of Interest

The authors declared no potential conflicts of interest with respect to the research, authorship, and/or publication of this article.

#### REFERENCES

- [1] World Health Organization. "COVID-19 weekly epidemiological update", 2021. <https://www.who.int/publications/m/item/weekly-epidemiological-update-on-COVID-19---11-may-2021>
- [2] Dashraath, Pradip, et al. "Coronavirus disease 2019 (COVID-19) pandemic and pregnancy." *American Journal of Obstetrics and Gynecology*, Vol. 222, No. 6, 2020, pp. 521-31.
- [3] Coronavirus infection and pregnancy, 2021. <https://www.rcog.org.uk/en/guidelines-research-services/guidelines/coronavirus-pregnancy/COVID-19-virus-infection-and-pregnancy/>
- [4] ICMR, NIRRH. "Guidance for management of pregnant women in COVID-19 pandemic. Indian Council of Medical Research." *National Institute for Research in Reproductive Health*, 2020. [https://www.icmr.gov.in/pdf/COVID/techdoc/Guidance\\_for\\_Management\\_of\\_Pregnant\\_Women\\_in\\_COVID19\\_Pandemic\\_12042020.pdf](https://www.icmr.gov.in/pdf/COVID/techdoc/Guidance_for_Management_of_Pregnant_Women_in_COVID19_Pandemic_12042020.pdf)
- [5] Joshi, K., et al. "A grave situation with COVID in the gravid: A narrative review." *International Journal of Research in Pharmaceutical Sciences*, Vol. 11, No. 1, 2020, pp. 496-99.
- [6] Singh, P., N. Acharya, and N. Verma. "Experience of managing COVID-19 suspected case in labour in a green zone district tertiary care hospital." *International Journal of Research in Pharmaceutical Sciences*, Vol. 11, No. 1, 2020, pp. 500-05.
- [7] Wang, Jing, et al. "Chest CT findings in a pregnant woman in the second trimester with COVID-19 pneumonia." *Clinical Imaging*, Vol. 69, 2021, pp. 266-68.
- [8] Burwick, Richard M., et al. "Compassionate use of remdesivir in pregnant women with severe coronavirus disease 2019." *Clinical infectious diseases: an official publication of the Infectious Diseases Society of America*, 2020.
- [9] Giampreti, Andrea, et al. "Medications prescriptions in COVID-19 pregnant and lactating women: The Bergamo Teratology Information Service experience during COVID-19 outbreak in Italy." *Journal of Perinatal Medicine*, Vol. 48, No. 9, 2020, pp. 1001-07.
- [10] Naqvi, Mariam, et al. "Tocilizumab and remdesivir in a pregnant patient with coronavirus disease 2019 (COVID-19)." *Obstetrics and Gynecology*, Vol. 136, No. 5, 2020, pp. 1025-29.